

Eye Biomarkers

*Early indicators of occupational toxicity:
Blood toxins, heavy metals and neurotoxins*

By Ahmed M. El-Sherbeeny, James V. Odom, Daniel E. Della-Giustina and James E. Smith

IT IS SAID THAT THE EYE is a window to the soul. Enough evidence exists from modern literature to show that the eye can express effects of various harmful toxins used in industry, arms development and some everyday applications. This article describes how three distinct categories of toxins—blood toxins, heavy metals and neurotoxins—present some distinct ocular symptoms or biomarkers. This may help early detection of a person's exposure to a certain toxin. In some cases, eye biomarkers also provide diagnostic evidence whereby a

Ahmed M. El-Sherbeeny, M.S., is a Ph.D. candidate in Mechanical Engineering at West Virginia University (WVU), where he has been a graduate teaching and research assistant. He holds a B.S. from the American University in Cairo and an M.S. in Mechanical Engineering from WVU. El-Sherbeeny is also an instructor for several undergraduate courses in engineering and mechanical engineering at WVU. He is a coinventor of Non-Invasive Ocular Dynamic Monitoring Assessment Method and Associated Apparatus, which received a U.S. patent in 2003. El-Sherbeeny's research interests include toxicology, facial recognition, and image remapping and optimization.

James V. Odom, Ph.D., is director of the West Virginia Lions Visual Function Laboratory and professor of ophthalmology and physiology at WVU. He is the group leader for the Vision Section of the West Virginia Healthy People 2010 plan. Odom has published more than 160 articles, book chapters and abstracts. His research has centered on clinical assessment of visual function using electrophysiology and psychophysics as means of assessing visual disability.

Daniel E. Della-Giustina, Ph.D., is a professor in the Department of Industrial and Management Systems Engineering and the Safety and Environmental Management Program at WVU. He holds a B.A. and an M.A. in Liberal Arts and Behavioral Sciences from American International College, and a Ph.D. in Safety, Health and Higher Education from Michigan State University. A professional member and Fellow of ASSE, Della-Giustina has published more than 100 articles and nine textbooks in the SH&E discipline, and he is currently editor of The Safety Forum, published by the School and Community Safety Society of America.

James E. Smith, Ph.D., is director of the Center for Industrial Research Applications and associate director for the Vision Enhancement Technology Center at WVU, where he is also a professor in the Mechanical and Aerospace Engineering Department. He holds a Ph.D. from WVU, and is a member of professional associations including ASME and ASEE. Smith has received several awards for teaching, research and service including the SAE Ralph R. Teeter Educational Award and the Academies of Distinguished Alumni Teaching Award.

certain ocular sign (or a series of signs) is manifested in the eye, unique to the particular toxin.

An example that involves both of these features is mercurialentis, a physically visible, unique discoloration of the lens that occurs due to mercurialism (mercury poisoning); it is also one of the earliest physical signs of mercurialism. Such evidence may help identify the type of toxin to which a person has been exposed, which would dictate proper treatment or antidote. Although not directly addressed in this article, recent technologies suggest the integration of signs of exposure indicated by the eye and other part of the body into an expert system (Odom, et al) or device that could lead to quick, accurate, cost-efficient diagnoses and possible treatment of common toxic reactions.

Blood Toxins

This category covers two extensively known and documented toxins: carbon monoxide (CO) and cyanide (CN). CO and CN are grouped because of the resemblance of their effects on oxygen-carrying capacity.

Carbon Monoxide

CO contributes to nearly half of the fatalities due to industrial emissions every year (McGregor). Table 1 (pg. 28) lists exposure limits for CO and other toxins discussed in this article. When inhaled, it binds with alveolar hemoglobin and forms carboxyhemoglobin (COHb), resulting in anemia (Block).

Ocular Manifestations

Eye symptoms due to CO depend mainly on the level of COHb. Levels of 10 to 20% COHb are accompanied by reddening of the conjunctiva and corneal ulceration (Hipwell). At 30 to 40%, visual defects include blurred and darkened vision. One common eye symptom is mydriasis (Leiken and Pauloucek). Retinopathy is a common CO disorder, existing as a "flame-shaped" hemorrhage (Photo 1). Mild edema of the optic disk is also recorded. Higher COHb levels cause amaurosis (partial sight loss), hemianopsia

(blindness in half of the visual field) and optic neuritis (Grant and Schuman).

Other Symptoms

High doses of CO usually induce unconsciousness and cause permanent damage to the central nervous system (CNS). The brain is the main target of chronic exposure to CO, mainly due to hypoxia (low oxygen supply). Signs include syncope (loss of consciousness), elevated intracranial pressure and possibly severe damage to brain tissue.

Prevention & Treatment

Proper ventilation is the most safe, least expensive preventive technique for toxicity. American Conference of Governmental Industrial Hygienists (ACGIH) suggests that workers be monitored for a COHb level of 8%, and air exposure not to exceed 40 ppm. Hyperbaric (high-pressure) oxygen and dopamine (stimulates cardiac output) are also used when neurological consequences are involved (Leiken and Pauloucek).

Cyanide

CN compounds are present in a large host of occupational applications including fertilizers, fumigation, pigments and electroplating (Leiken and Pauloucek). When administered to the body (mainly via inhalation), CN ions react with cytochrome oxidase (A₃) enzymes that restrain use of cellular oxygen, leading to hypoxia (Hughes; MacLeod; Plunkett). Another enzyme, rhodanese, then modifies the compound into a less-harmful thiocyanate, which is finally excreted by the kidneys (Ballantyne). The abundance of vitamin B₁₂ (a cyanide compound) in the eye serves as evidence of excessive CN absorption. Other ocular indicators triggered by CN are optic neuropathy and optic atrophy.

Ocular Manifestations

The large literature collection on eye symptoms resulting from exposure to CN compounds may supply enough reason to conclude that physical ocular examination and evaluation may be superior to the alternative of testing whole-blood cyanide levels (Lizarralde, et al). The retina and optic nerve are the primary targets of acute cyanide exposure. Mydriasis commonly occurs at a sublethal cyanide concentration. A child lethally poisoned with cyanide was found to have retinal edema. Also, a man poisoned with hydrocyanic acid (HCN) during fumigation was found to have a corneal edema hours later, followed by a Kayser-Fleischer pigmented ring (a pigmented ring at the outer edge of the cornea of the eye as shown in Photo 2) (Grant and Schuman). Eye symptoms due to chronic CN exposure are as yet inconclusive.

Other Symptoms

Severity and duration of exposure are usually the main determinant of symptoms caused by CN. Following acute exposure, patients either fully recover or die. The CNS is severely affected by exposure to cyanide. Chronic symptoms include metallic taste, harshness of voice, dizziness, nausea, weakness and dermatitis (skin inflammation). Cyanosis is a discoloration of the skin due to insufficient oxygen reaching the blood cells (Grant and Schuman).

ation of the skin due to insufficient oxygen reaching the blood cells (Grant and Schuman).

Prevention & Treatment

Exposed eyes should be thoroughly washed to limit effects of local toxicity (Ballantyne). Atropine is frequently used to heal eye congestion (Grant and Schuman). Hydroxocobalamin (a B₁₂ vitamin) is an efficient antidote for systemic eye symptoms due to cyanide. Cataracts and other lens opacities can be easily treated with aspirin and ibuprofen.

Heavy Metals

By definition, the only real heavy metals are mercury, thallium, lead and bismuth, with atomic weights 200 to 210, present as irreversible, complex compounds. All heavy metal ions are extremely toxic and reactive (Foulkes). Although not heavy metals, arsenic and uranium have shared characteristic and toxic resemblances (Crosby).

Arsenic

Arsenic (AS) exists in an organic or inorganic (more toxic) state. One of the most toxic forms is arsine gas, where nearly one quarter of exposure cases has resulted in death [Leiken and Pauloucek; Proctor, et al; NIOSH(a)]. Arsenic is used in microchips, preservatives, soaps and paints (Timbrell; Winder). Arsenic is introduced into the body mainly via inhalation. After blood absorption, it is reduced into the less-toxic arsenite, then finally excreted in the urine.

Ocular Manifestations

Ocular manifestations of arsenic poisoning (organic or inorganic) are mainly chronic and primarily occur on the external eye within 1 to 6 weeks following exposure. They include conjunctivitis, corneal necrosis (Photo 3), lacrimation, and weakening of intraocular and extraocular muscles (Block; Leiken and Pauloucek; Plunkett). Eyelid disorders include ptosis (drooping of upper eyelid), edema and eyelid melanosis (abnormal depositing) (Harbison and Garvey). Visual disorders include diminished eyesight and constriction of the visual field (Grant and Schuman; Proctor, et al). Optic nerve spots, conjunctivitis, watery eyes and visual disorders have all been reported by NIOSH in several documented case studies [NIOSH(a)].

Other Symptoms

Symptoms due to arsenic are typically chronic, occur within 3 weeks of exposure and mainly target the CNS (Winder). This includes neuropathy, encephalitis (brain inflammation) and liver damage

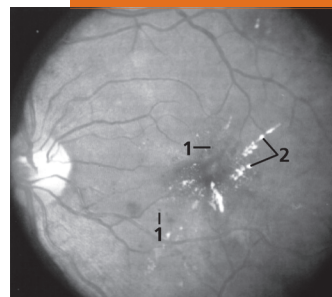


Photo 1 (top): Example of retinopathy. Microaneurysms (1) and flame-shaped hemorrhages (2) similar to that caused by CO poisoning.




Photo 2 (middle): Kayser-Fleischer ring appearing on the descemet membrane of the peripheral cornea (similar to that resulting from acute exposure to hydrocyanic acid).

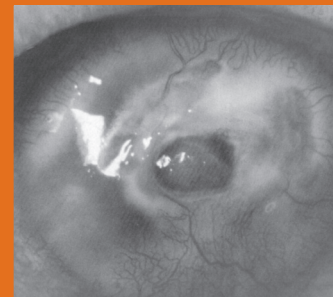


Photo 3 (bottom): Stromal corneal necrosis and perforation due to local alkaline exposure similar to that due to arsenic poisoning.

Abstract: This literature review examines the eye toxicity of three categories of toxins: blood toxins, metals and neurotoxins. It discusses their characterization, mechanism of action, treatment and ocular manifestations. Eye symptoms are classified according to either degree of toxicity or affected region of the eye. The objective is to offer information on the eye's explicit expression of early and unique signs of toxicity. It also provides SH&E professionals with a guide that may facilitate the proactive detection, assessment and efficient treatment of exposure to these occupational toxins.

(Leiken and Pauloucek; Ostler, et al; Proctor, et al). A common biomarker is jaundice (Harbison and Garvey; Lu). Symptoms due to high doses of arsenic include bloody diarrhea and cramps (Lu).

Prevention & Treatment

Blood levels (due to short half-life) are not considered “reliable indicators of arsenic exposure” (Harbison and Garvey). Currently, a urine threshold ranging from 0.05 to 1.0 mg of arsenic is used (Leiken and Pauloucek). Exposure is treated with dimercaprol (antilewisite used since WWII) (Plunkett), as well as penicillamine and succimer (used in treating metal poisoning).

Mercury

Mercury (Hg) derivatives exist in metallic, organic or inorganic form (Proctor, et al). Mercury vapor (both organic and inorganic) is one of the most toxic forms. Mercury compounds are used as seed fungicides, sterilizing agents and in the treatment of corneal ulcers (Grant and Schuman; Zelikoff and Thomas). The use of methyl mercury as an alloy has led to several epidemics around the world, including the Minamata disease, which caused 70 fatalities.

Inhaled or ingested mercuric ions are transferred to the blood and deposited to body tissues, restraining cellular enzymes (Ostler, et al; Timbrell).

Ocular Manifestations

Eye signs of mercurialism occur chiefly on the visual cortex and are mostly chronic (Lu). Signs include photophobia (intolerance to light), mercurialentis (unique coating of the lens), circular corneal opacities (Photo 4), eyelid tremors (Lizarralde, et al), partial loss of vision (Block; Plunkett) and severe constriction of peripheral visual fields (Ostler, et al; Spehar; Zelikoff and Thomas). Several cases of constricted visual fields were reported with Italian hatters and Polish environmental workers (red mercury vapor). Metallic mercury (inorganic) remains as a host particle in the circulation and may reach the eye systemically; this may cause band keratopathy (corneal disease) and eyelid inflammation (mercury fulminate) (Spehar).

Other Symptoms

The main targets of mercury are the CNS, respiratory system and kidneys, which retain mercury the most. The inhalation of mercury compounds contributes to bronchitis, muscle aches and vomiting

Table 1

Standard Exposure Limits

Compound	PEL ^a	REL ^b	TLV ^c
Carbon monoxide			
Lower limit	55 mg/m ³ or 50 ppm	40 mg/m ³ or 35 ppm	29 mg/m ³ or 25 ppm
Maximum	229 mg/m ³ or 200 ppm	200 ppm	
Hydrogen cyanide	11	5	5
Sodium/potassium cyanide	5	5	5
Cyanogen chloride		0.6	0.75
Arsenic			
Inorganic	0.01	0.002	0.01
Organic	0.5		
Arsine		0.002	0.2 mg/m ³ or 0.05 ppm
Alkyl mercury (organic)	0.01, ceiling limit: 0.04	0.01, IDLH ^d : 2	0.01, STEL ^e : 0.03
Mercury vapor (inorganic)			0.05
Lead	0.05 mg/m ³ (inorganic lead and organic soaps)	0.1 mg/m ³ (metallic lead, lead oxides, and lead salts and soaps)	0.05 mg/m ³ (elemental and inorganic lead)
Lead arsenate			0.15 mg/m ³
Uranium		0.05 mg/m ³	0.2 mg/m ³
Parathion			0.1 mg/m ³
Malathion			10 mg/m ³
Carbaryl			5 mg/m ³

Note: Standard threshold limits by ACGIH, NIOSH and OSHA for carbon monoxide, cyanide compounds, arsenic compounds, mercury compounds, lead compounds, uranium, organophosphates and carbaryl.

^aPEL: permissible exposure limit set by OSHA. ^bREL: recommended exposure limit set by NIOSH. ^cTLV: threshold limit value set by ACGIH. ^dIDLH: immediately dangerous to life or health (NIOSH). ^eSTEL: short-term exposure limit (ACGIH).

(Plunkett; Proctor, et al; Zelikoff and Thomas). Acrodynia (pain in the extremities) occurs with children as a unique symptom of mercury poisoning.

Prevention & Treatment

Atkinson's brownish reflection is a technique currently used to detect mercurialentis from the lens capsule (Spehar). Mercuric oxide is employed in the topical eye treatment of mercury exposure, mercuric sulfide for treating corneal opacities and phenylmercuric salts for glaucoma. Hemodialysis has been effective in removing mercury from the blood.

Lead

Lead (Pb) exists in different forms (19 inorganic and 2 organic) and isotopes (4 natural and 17 artificial) [Harbison(b)]. Lead enters the body mainly through inhalation of dusts or fumes (ACGIH). The largest numbers of victims affected by lead are children ages 1 to 5 (Olson, et al). Uses of lead include soldering, printing media and insecticides (lead arsenate) (Proctor, et al). Sources of exposure include mining, paints, glass and wines. Following inhalation, lead particulates are deposited in the lungs and absorbed into circulation, disrupting heme production.

Ocular Manifestations

Lead accumulates systemically in the eye (even at subclinical concentrations), causing various ocular manifestations that can act as early signs of toxicity. Eye disorders occur within the visual cortex, as well as in the optic nerve, retina, and extraocular and intraocular muscles (Grant and Schuman). Ocular disorders caused by lead have been reported for the last 350 years (Proctor, et al), yet have often been inappropriately described in terms of nature, site or mechanism. Eye signs include strabismus (squint), palsies (uncontrollable tremors) of extraocular eye nerves, papilledema (Photo 5), optic atrophy and degeneration of retinal blood vessels. Saccadic eye movements and abnormal smooth eye pursuit are commonly used to measure effects of chronic lead among lead workers (NIOSH).

Other Symptoms

Other manifestations of lead poisoning occur soon after exposure and mainly affect the CNS and kidneys. Symptoms include vomiting, convulsions, learning problems, anemia and hyperactivity (Harbison). Colica Pictonum is a chronic disease of the CNS caused by lead-containing wines, with symptoms including learning difficulties (Olson, et al).

Prevention & Treatment

Regular testing for lead is done by measuring blood, urine or bone levels (Plunkett; Proctor, et al). Currently, the best indication of lead exposure is to monitor blood levels for enzymes ALA and protoporphyrin. However, this method has not proven highly reliable. Chelating agents typically used include calcium EDTA, succimer, penicillamine and dimercaprol.

Uranium

Uranium is a highly toxic carcinogen (Plunkett; Proctor, et al), naturally present as a stable nonreacting

mixture of three isotopes: uranium-234, uranium-235 and uranium-238 (AIHA; Crosby; Zakrzewski). Exposure to uranium involves gamma rays, dust particles and radon gas (Winder). Occupational exposure to uranium can occur in industries such as mining, nuclear power and arms development (e.g., depleted uranium) (AIHA; Corbella and Domingo; Crosby; Goyer, et al; Nussbaum and Kohnlein). According to NIOSH and OSHA, exposure to uranium occurs primarily via inhalation and ingestion. For the soluble compounds, the uranyl ion is absorbed by the blood where it is changed into a stable bicarbonate form that accumulates in the liver, causing liver or kidney failure. Within 24 hours, about 60% is excreted via the kidneys and about 25% resides in bone structure (Crosby; Foulkes).

Ocular Manifestations

Little literature is available regarding uranium's eye toxicity and "significant gaps still remain in the knowledge of the chemical toxicity of uranium in animals" (Corbella and Domingo). Systemic eye intoxication of uranium is primarily assessed through animal testing, where cataracts have been indicated in several case studies (NIOSH/OSHA; Proctor, et al). The eye shows signs of irritation at low, chronic exposure to uranium. Optic atrophy (Photo 6) occurred in an experiment to test the systemic effects of uranium nitrate on rabbit eyes (Grant and Schuman).

Other Symptoms

Other manifestations caused by uranium are mostly chronic and include jaundice (Block; Plunkett) and chronic lung diseases (e.g., cancer) (Proctor, et al; Winder; Zakrzewski). Other symptoms include dermatitis, skin lesions and weight loss (Crosby; Leiken and Pauloucek). Uranium also affects the reproductive system (Corbella and Domingo).

Prevention & Treatment

Examination of exposed workers once every 6 months for the health of their liver and kidneys is one way to monitor uranium toxicity levels. The eyes should be washed with water in case of direct contact with uranium (Plunkett). As an antidote, sodium

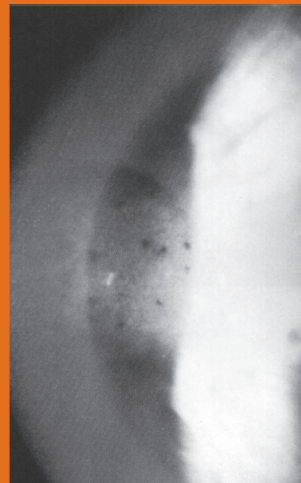


Photo 4 (top, left): Mercury deposits on the Bowman layer (cornea) induced topically.

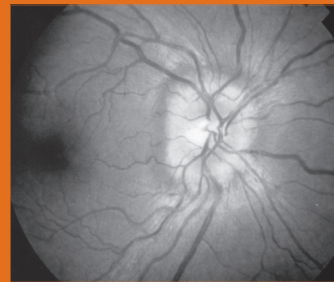


Photo 5 (top, right): Chronic papilledema with signs of mild vascular congestion.

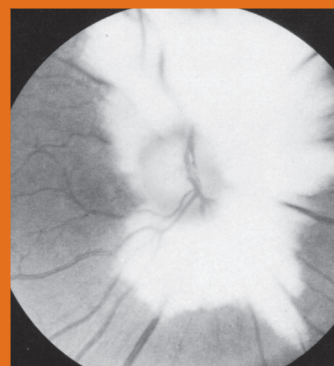


Photo 6 (bottom, right): Dominant optic atrophy (possible visual loss).

Photo 7 (right): Acute angle-closure glaucoma; severely high intraocular pressure resulted in eye inflammation, in addition to corneal edema and a partially dilated pupil (note also the disturbed light reflex).

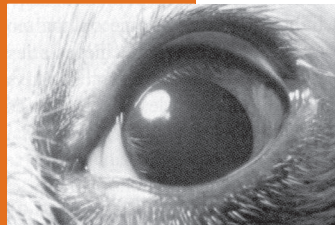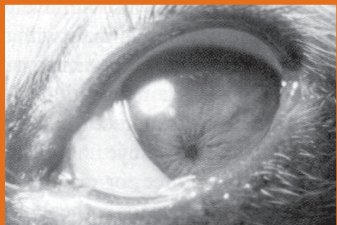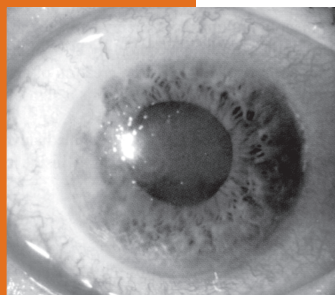


Photo 8 (above): Using atropine to treat miosis. (Left): Miosis due to corneal foreign body in a dog. (Right): Mydriasis after treatment with atropine.

bicarbonate is applied. Edathamil calcium disodium (EDTA) is also recommended for supportive treatment (Leiken and Pauloucek; Plunkett).

Neurotoxins

Pesticides and nerve gases are two types of neurotoxic anticholinesterases (antiChEs), substances that restrain the action of cholinesterase enzyme, crucial for liver performance. AntiChEs can be used as

miotics and in treating ocular symptoms such as ptosis, diplopia (double vision) and glaucoma.

Pesticides

Major sources of pesticide exposure include contaminated water and industrial wastes (Ballantyne and Marrs). Organophosphates (OPs) and carbamates (CBs) are widely used as pesticides. Exposure to OPs can occur by way of inhalation, the skin, ingestion (e.g., malathion) or by direct exposure of the eye (e.g., parathion). The liver handles most of the excretion (Proctor, et al). Carbaryl is a common CB, used mainly as an insecticide (Block; Grant and Schuman).

Ocular Manifestations

Ocular manifestations of OPs and CBs were extensively studied by Erickson-Lamy and Grant in 1992 (Erickson-Lamy and Grant). Cholinesterase restraining and subsequent eye symptoms occur with direct and systemic exposure. A series of controversial poisoning cases occurred in Japan, known as the "Saku disease," where OPs directly targeted vision (Grant and Schuman). Eye disorders related to exposure to OPs include miosis, nystagmus (jerky eye movement) and acute angle-closure glaucoma (Photo 7). Miosis, lacrimation and diminished vision are encountered with carbaryl poisoning (Block).

Other Symptoms

Restraining of cholinesterase enzymes due to OPs leads to acetylcholine accumulation, causing various nervous system, skeletal and muscular disorders (Proctor, et al). A unique disturbance of OPs is called "delayed distal axonopathy," which affects the arms and legs but has no ocular manifestations.

Prevention & Treatment

A currently applied method of preventing OP intoxication is monitoring the level of cholinesterase in the blood. Urinary levels are also commonly used to monitor carbaryl levels (Proctor, et al). Pralidoxime is a popular antidote, induced systemically to treat intoxication of OPs and nerve gases (Proctor, et al). Directly applied antitoxins used to cure OP and CB symptoms include anticholinergic

eye drops and atropine (Photo 8) to relieve miosis into mydriasis and eventually into normal dilation.

Sarin

Nerve gases (including sarin, tabun and soman) are used in chemical warfare to paralyze victims (Ballantyne and Marrs). Sarin poisonings in Japan affected 600 people in 1994, and 5,500 in 1995 (Grant and Schuman; Yokoyama, et al). The poison acts through direct skin contact in its liquid form, ingestion or inhalation of the gas (Yokoyama, et al).

Ocular Manifestations

Sarin is reported to cause cyclotonia, conjunctival reddening and restricted visual accuracy in faint light. Sarin also causes temporary miosis (Proctor, et al). On one occasion, it produced extreme miosis as an immediate reaction to acute exposure. The byproduct of sarin production, difluoro, has also been noted to cause eye irritation and corneal opacity following direct eye exposure (Grant and Schuman).

Other Symptoms

Common symptoms of exposure to nerve gases include dizziness and loss of balance. Sweating and salivation are often noted, as is a unique change in the color of the nails (Block).

Prevention & Treatment

Blood levels are used to determine exposure levels of nerve gases, with similar exposure indices as with OPs. Cyclopentolate (anticholinergic) eye drops are used topically to treat miosis and cyclotonia due to sarin gas.

Conclusion

The toxins reviewed in this article cause some form of ocular manifestation, which can be classified according to the affected region of the eye, or by the method of administration or exposure. Ocular regions include exterior regions (e.g., sclera, eyelids, cornea), interior regions (e.g., retina, optic nerve) or nonphysical phenomena that are quantified by various visual or experimental measures (e.g., visual field, EEG). Extraocular manifestations and measures are especially advantageous for the early detection of toxicity, while internal eye effects and measures could be beneficial in quantifying and analyzing damage to the CNS and other parts of the body affected by the toxin.

Toxic exposure is either systemic (e.g., by ingestion or via the skin) or local (i.e., direct eye exposure). This classification serves to show how eye biomarkers can express themselves uniquely and profoundly even when exposure occurs systemically. These results are illustrated in Table 2.

The more immediate ocular manifestations of CO, such as reddening of the conjunctiva and corneal ulceration, occur at relatively low levels of exposure. Extraocular symptoms are also more prominent than intraocular signs for cyanide (e.g., corneal edema and distinctive vitamin B₁₂ deposits), many of which only appear several hours following exposure. For heavy metals, it is observed that

Table 2

Ocular Manifestations of Reviewed Toxins

Ocular manifestations of reviewed toxins are classified by affected region of the eye (exterior or interior eye regions) or by functional measures (e.g. vision effects, EEG measures); furthermore, ocular manifestations are classified as either due to S, systemic (indirect) or L, local (direct) exposure.

Affected eye region	Toxin (including compounds)													
	CO		CN		As		Hg		Pb		U		antiChEs	
	S	L	S	L	S	L	S	L	S	L	S	L	S	L
External eye														
Pupil	✓		✓					✓		✓			✓	✓
Iris			✓				✓	✓					✓	
Eyelids			✓		✓		✓	✓			✓		✓	
Tear glands			✓	✓	✓	✓	✓	✓			✓		✓	
Extraocular muscles			✓	✓	✓	✓	✓		✓				✓	
Cornea	✓	✓	✓	✓	✓	✓	✓	✓			✓		✓	
Conjunctiva	✓	✓	✓	✓	✓	✓	✓	✓			✓	✓		
Sclera			✓		✓		✓							
Ciliary body													✓	
Lens			✓				✓	✓		✓	✓			
Internal eye														
Vitreous humor					✓	✓				✓				
Retina	✓		✓		✓	✓	✓	✓	✓	✓			✓	
Optic nerve			✓		✓		✓		✓		✓			
Optic disk	✓				✓		✓		✓					
Eye blood vessels			✓		✓	✓		✓	✓					
Intraocular muscles					✓		✓		✓				✓	
Functional measures														
Vision	✓		✓		✓	✓	✓		✓				✓	✓
Visual fields	✓				✓		✓		✓				✓	
ERG, EEG, EOG, VER	✓		✓				✓		✓				✓	

arsenic and mercury deliver a large host of external and internal eye signs. In addition, mercurialentis is a unique sign and a means of early detection of exposure to mercury.

Lead has dominance for internal eye symptoms, although chronic lead exposures distinctly cause abnormal saccadic eye movements; it accumulates systemically even at low concentrations. The majority of eye symptoms due to uranium occur on the exterior eye, including conjunctivitis and cataracts. Neurotoxins, including pesticides, carbamates and nerve gases, mainly cause miosis (and mydriasis in some cases) as well as target vision. This article should thus highlight the significant role of early and unique eye symptoms in the possible identification of exposure to select blood toxins, heavy metals and neurotoxins. ■

References

American Conference of Governmental Industrial Hygienists (ACGIH). *Threshold Limit Values (TLVs) for Chemical Substances*

and *Physical Agents and Biological Exposure Indices (BEIs)*. Cincinnati, OH: ACGIH, 1996.

American Industrial Hygiene Association. "Uranium (Natural) and Its Compounds; U." *AIHA Journal*. 30(1969): 313-317.

Anderson, K. and R. Scott. *Fundamentals of Industrial Toxicology*. Ann Arbor, MI: Ann Arbor Science, 1981.

Ballantyne, B. "Toxicology and Hazard Evaluation of Cyanide Fumigation Powders." *Journal of Clinical Toxicology*. 26(1988): 325-335.

Ballantyne, B. and T.C. Marrs. "Overview of the Biological and Clinical Aspects of Organophosphates and Carbamates." In *Clinical and Experimental Toxicology of Organophosphates and Carbamates*, B. Ballantyne and T.C. Marrs, eds. Oxford: Butterworth-Heinemann, 1992. 3-14.

Beck, A.D. "Glaucoma." In *Ophthalmology for the Primary Care Physician*, D.A. Palay and J.H. Krachmer, eds. St. Louis, MO: Mosby, 1997. 135-142.

Block, J.B. *The Signs and Symptoms of Chemical Exposure*. Springfield, IL: Thomas, 1980.

Collins, B.K. "Atropine: An Eye Opener." *Veterinary Technician*. 15(94): 404-407.

Corbella, J. and J.L. Domingo. "Developmental and Reproductive Effects of Aluminum, Manganese, Uranium and Vanadium." In *Toxicology of Metals*, L.W. Chang, et al, eds. Boca Raton, FL: Lewis, 1996. 1083-1096.

Glossary of Selected Terms

- carbamate (CB):** a salt or ester of carbamic acid; especially one that is a synthetic organic insecticide.
- chronic:** a disease marked by long duration or frequent recurrence (the opposite of acute).
- conjunctivitis:** inflammation of the conjunctiva.
- depleted uranium:** left over when the highly radioactive isotopes of uranium are removed for use as nuclear fuel or nuclear weapons.
- edema:** an abnormal infiltration and excess accumulation of fluid in connective tissue (leading to swelling).
- lacrimation:** the secretion of tears especially when abnormal or excessive.
- miosis:** excessive contraction of the pupil.
- mydriasis:** a long-continued or excessive dilatation of the pupil.
- optic atrophy:** paleness of the optic nerve; caused by toxic damage (e.g., lead poisoning) or triggered by Leber's disease.
- optic neuritis:** inflammation of the optic nerve.
- optic neuropathy:** severely blinding disease resulting from loss of the arterial blood supply to the optic nerve.
- organophosphates (OP):** phosphorus-containing organic compounds that irreversibly inhibit cholinesterase enzyme.
- retinopathy:** any of various noninflammatory disorders of the retina, including some that cause blindness.

References

- Cline, D., H.W. Hofstetter and J.R. Griffin. *Dictionary of Visual Science*. 3rd ed. Radnor: Chilton, 1980.
- On-Line Medical Dictionary. <<http://cancerweb.ncl.ac.uk/omd>>.
- Stein, H.A., B.J. Slatt and R.M. Stein. *Ophthalmic Terminology*. 3rd ed. St. Louis: Mosby, 1992.
- Walsh, T.J. *Neuro-Ophthalmology. Clinical Signs and Symptoms*. 4th ed. Baltimore: Williams, 1997.
- WWWebster Dictionary. <<http://www.m-w.com>>.
- Crosby, D.G.** *Environmental Toxicology and Chemistry*. New York: Oxford, 1998.
- Erickson-Lamy, K. and W.M. Grant.** "Ophthalmic Toxicology of Anticholinesterases." In *Clinical and Experimental Toxicology*, B. Ballantyne and T.C. Marrs, eds. Oxford: Butterworth, 1992. 180-194.
- Foulkes, E.** "Metal Disposition: An Analysis of Underlying Mechanisms." In *Metal Toxicology*, R.A. Goyer, et al, eds. San Diego, CA: Academic, 1995. 3-29.
- Goyer, R.A., et al, eds.** *Metal Toxicology*. San Diego, CA: Academic, 1995.
- Grant, W.M. and J.S. Schuman.** *Toxicology of the Eye. Effects on the Eyes and Visual System from Chemicals, Drugs, Metals and Minerals, Plants, Toxins and Venoms*. 4th ed. Springfield, IL: Thomas, 1993.
- Greenberg, M.I., ed.** *Occupational, Industrial and Environmental Toxicology*. St. Louis, MO: Mosby, 1997.
- Hamilton, A.M., et al.** *Text Atlas of the Retina*. Boston: Dunitz, 1998.
- Harbison, R.D., ed.(a).** *Hamilton and Hardy's Industrial Toxicology*. 5th ed. St. Louis, MO: Mosby, 1998.
- Harbison, R.D.(b).** "Lead." In *Hamilton and Hardy's Industrial Toxicology*, 5th ed., R.D. Harbison, ed. St. Louis, MO: Mosby, 1998. 70-77.
- Harbison, R.D. and G.J. Garvey.** "Arsenic." In *Hamilton and Hardy's Industrial Toxicology*, 5th ed., R.D. Harbison, ed. St. Louis, MO: Mosby, 1998. 28-33.
- Hipwell, F.** "Suspected Carbon Monoxide Poisoning in a Dog." *Veterinary Record*. March 18, 1995: 275-276.
- Hughes, W.W.** *Essentials of Environmental Toxicology: The Effect of Environmentally Hazardous Substances on Human Health*. Washington, DC: Taylor, 1996.
- Krachmer, J.H. and D.A. Palay.** *Cornea Color Atlas*. St. Louis, MO: Mosby, 1995.
- Leiken, J.B. and F.P. Pauloucek.** *Poisoning & Toxicology Handbook*. Hudson, OH: Lexi-Comp, 1995-96.
- Lizarralde, S.M., et al.** "Jewelers." In *Occupational, Industrial and Environmental Toxicology*, M.I. Greenberg, ed. St. Louis, MO: Mosby, 1997. 153-70.
- Lu, F.C.** *Basic Toxicology: Fundamentals, Target Organs and Risk Assessment*. 3rd ed. Washington, DC: Taylor, 1996.
- MacLeod, S.** "Cyanide." In *Hamilton and Hardy's Industrial Toxicology*, 5th ed., R.D. Harbison, ed. St. Louis, MO: Mosby, 1998. 171-176.
- McGregor, J.M.** "Carbon Monoxide." In *Hamilton and Hardy's Industrial Toxicology*, 5th ed., R.D. Harbison, ed. St. Louis, MO: Mosby, 1998. 165-170.
- NIOSH(a).** "Criteria for a Recommended Standard: Occupational Exposure to Inorganic Arsenic: New Criteria—1975." Washington, DC: U.S. Department of Health, Education and Welfare, NIOSH, 1975.
- NIOSH(b).** *Pocket Guide to Chemical Hazards*. DHHS/NIOSH Publication No. 94-116. Washington, DC: U.S. Department of Health and Human Services, Centers for Disease Control and Prevention, NIOSH, 1994.
- NIOSH/OSHA.** *Occupational Health Guidelines for Chemical Hazards*. Washington, DC: U.S. Department of Health and Human Services, Centers for Disease Control and Prevention, NIOSH, 1981.
- Nussbaum, R.H. and W. Köhnlein.** "Ionizing Radiation." In *Occupational, Industrial and Environmental Toxicology*, M.I. Greenberg, ed. St. Louis, MO: Mosby, 1997. 517-530.
- Odom, J.V., et al.** "Non-Invasive Ocular Toxicity Assessment Instrument: Number Three, Dynamic Monitoring." U.S. Patent 6,626,537 B1. Morgantown, WV: West Virginia University, 2003.
- Olson, L., et al.** "Some Toxic Effects of Lead, Other Metals and Antibacterial Agents on the Nervous System: Animal Experiment Models." *Acta Neurologica Scandinavica Supplement*. 100(1984): 77-87.
- Olson, T.W.** "The Retina." In *Ophthalmology for the Primary Care Physician*, D.A. Palay and J.H. Krachmer, eds. St. Louis, MO: Mosby, 1997. 102-134.
- Ostler, N.K., et al.** *Health Effects of Hazardous Materials*. Vol. 3 of 6 in *Prentice Hall's Environmental Technology Series*. Upper Saddle River, NJ: Prentice Hall, 1996.
- Plunkett, E.R.** *Handbook of Industrial Toxicology*. New York: Chemical Publishing, 1966.
- Proctor, N.H. et al.** *Chemical Hazards of the Workplace*. 2nd ed. Philadelphia: Lippincott, 1988.
- Spehar, A.** "Mercury." In *Hamilton and Hardy's Industrial Toxicology*, 5th ed., R.D. Harbison, ed. St. Louis, MO: Mosby, 1998. 84-96.
- Timbrell, J.A.** *Introduction to Toxicology*. 2nd ed. London: Taylor, 1995.
- Verity, A.M.** "Nervous System." In *Metal Toxicology*, R.A. Goyer, et al, eds. San Diego, CA: Academic, 1995. 199-236.
- Winder, C.** "Toxicity of Metals." In *Occupational Toxicology*, N.H. Stacey, ed. London: Taylor, 1993. 165-176.
- Yokoyama, K., et al.** "Chronic Neurobehavioral Effects of Tokyo Subway Sarin Poisoning in Relation to Posttraumatic Stress Disorder." *Archives of Environmental Health*. 53(1998): 249-256.
- Zakrzewski, S.F.** *Principles of Environmental Toxicology*. 2nd ed. Washington, DC: ACS Monograph, 1997.
- Zelikoff, J.T. and P.T. Thomas.** *Immunotoxicology of Environmental and Occupational Metals*. London: Taylor, 1998.